

Malocclusions – linguoverted mandibular canines - "Ball Therapy"

Malocclusions (abnormal bites) in dogs are common problems that our **Dentistry & Oral Surgery Service** addresses.

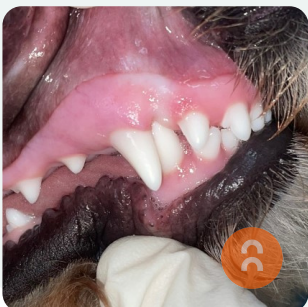
One of Dr Kevin's strategies for a specific malocclusion known as linguoverted mandibular canines (also sometimes known as base-narrow canines) is "Ball Therapy", which some of you may have heard of. However, what many people don't realise is that there are many factors that play a role in whether "Ball Therapy" will be effective.

The pattern of malocclusion, the age of the dog, the size of the ball and the duration and type of chewing activity are all vital in determining success. During an orthodontic (bite evaluation) consultation with our Dentistry & Oral Surgery Service, Dr Kevin will perform a complete bite evaluation, determine if "Ball Therapy" is the best option for your dog, provide the right size of the ball, and create a customized treatment plan for your pet.

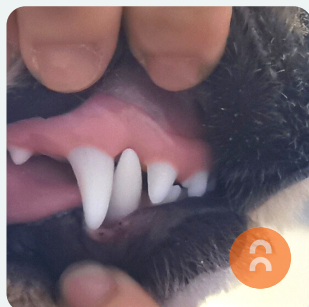
Pictured below is "Miso", a 7-month-old poodle who was presented to see Dr Kevin with linguoverted mandibular canines.

In the before photos, you can see her lower canine teeth digging up into the roof of her mouth. OUCH!!!

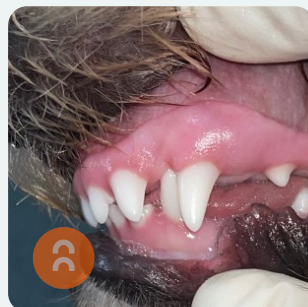
The after photos show the results of several weeks of "Ball Therapy" at home under the guidance of Dr Kevin. Miso's teeth are now in the correct position, and no longer causing any damage to the roof of her mouth. Due to the success of this treatment plan, Miso was able to avoid further orthodontic procedures requiring a general anaesthetic.



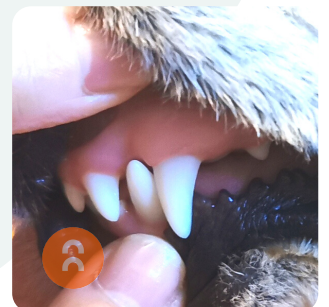
Before



After



Before



After